

## ORIGINAL ARTICLE



## Study of Prognostic and Diagnostic Significance of P53 and PTEN Mutation in Proliferative Lesions of Endometrium

Dr. Suchandra Ray<sup>1</sup> | Dr. Ashish Jha<sup>2</sup> | Dr. Ayesha Afreen Islam<sup>3\*</sup> | Dr. Moumita Sengupta

<sup>1</sup>Associate Professor, Department of Pathology, Institute of Post Graduate Medical Education and Research

<sup>2</sup>Senior Resident, Department Of Pathology, Jipmer.

<sup>3</sup>Demonstrator, Department of Pathology, Institute of Post Graduate Medical Education and Research

<sup>4</sup>Associate professor, Department of Pathology, IPGIMER, kolkata.



### Abstract

**Background:** Endometrial hyperplasia essentially implies an over-growth of the endometrium. Complex hyperplasia associated with cellular atypia, seems to be the most important predictor of malignant potential. Endometrioid Endometrial Carcinomas account for three-fourths of Endometrial Carcinomas and are thought to develop following a continuum of premalignant lesions ranging from endometrial hyperplasia without atypia, to hyperplasia with atypia, and finally to well-differentiated carcinoma. Currently the most frequently observed gene mutation in endometrioid carcinoma is located on chromosome 10 and is related with the PTEN gene (phosphatase and tensin homolog). PTEN inactivation is found to correlate with clonal growth pattern detected in endometrial hyperplasia and carcinoma. The p53 tumor suppressor gene locates to chromosome 17p13. The abnormal p53 expression has been found in 11% of grade 1 endometrioid endometrial carcinoma, while p53 mutations occur in 90% of non-endometrioid endometrial carcinoma.

**Aims and objectives:** In this study we aim to evaluate the immuno histochemical expression of P53 and PTEN genes in endometrial hyperplasia and endometrial carcinoma and correlate their expression with prognostic outcomes like grade and stage, in cases of endometrial carcinoma.

**Material and methods:** A prospective study of 60 patients with abnormal uterine bleed in the peri and post menopausal age was conducted, for a period of three years. Histological specimens were studied for HPE and IHC for the markers PTEN and P53.

**Results:** The mean age for hyperplastic and carcinomatous lesions was 44.9 years and 53.2 years respectively. 35% (21 cases) were endometrial hyperplasia and 65% (39 cases) of cases were endometrial carcinoma. Among endometrial carcinoma 87% are of endometrioid type and 13% are of other types, which include serous, clear and malignant mixed Mullerian type of carcinoma. IHC study showed that PTEN expression is higher in endometrial hyperplasia than endometrial carcinoma cases. Elevated P53 expression correlated with poor differentiation of endometrial cancer. P53 was found to be more in cases with FIGO staging III & IV compared to stage I & II (100% vs 18.1% p value= 0.0016) and grade 3 compared to grade 1&2 (50% vs 0 p value= 0.0116).

**Conclusion:** Immuno histochemical biomarkers like PTEN and P53 may contribute to better tumor characterization and thus more precisely determine its clinical behavior.

**Key words:** Endometrial Hyperplasia, Endometrial Carcinoma, PTEN, P53.

## 1 | INTRODUCTION:

Endometrial carcinoma is the most common neoplasm of the female genital system. When the frequency rate is examined in developed countries, it is the fourth most common carcinoma. (1) The histology of the normal endometrium is characterized by a well-controlled hormone dependent menstrual cycle. (1) The proliferative lesions of endometrium comprise of endometrial hyperplasia which may be associated with or without atypia. In many cases hyperplasia predisposes a carcinoma. (2) About 70-80% of type I endometrial adenocarcinoma cases occur on a background of endometrial hyperplasia which along with endometrial intraepithelial neoplasia is considered as a precursor lesion. (3) Histopathologically, endometrial carcinoma can be classified as endometrioid and its variants mucinous, serous, clear cell, neuroendocrine, mixed, undifferentiated, or dedifferentiated. Additionally, a small percentage of carcinomas demonstrate mesenchymal differentiation and are referred to as carcinosarcoma. (3) The prognosis of the histological variants of endometrial carcinoma differs, depending on the type, grade and depth of myometrial invasion, and stage (4).

In the last decades, studies aimed at analyzing the human genome identified additional factors, particularly in molecular and cellular level concerning the pathogenesis of endometrial carcinoma. (5) Specifically, several DNA mutations concerning proteins involved in mechanisms of cell signal transduction and communication have been investigated. (5) Among them, the most frequently observed gene mutation is located on chromosome 10 and is related with the PTEN gene (phosphatase and tensin homolog). (5, 6) It belongs to the group of tumor suppressor genes and decreased PTEN activity causes increased cell proliferation and survival through modulation of signal transduction pathways. (6) A positive PTEN expression correlates significantly with hyperplasia without atypia and well-differentiated tumors. The down regulation of PTEN indicates a more malignant phenotype. (7) Due to frequent PTEN loss in endometrial tumors, the PTEN- PI3K –AKT pathway is a rational target for the treatment of endometrial cancer. (8) Inhibitors

to MTOR, PI3K and AKT, all of which target this pathway, are currently in development. PTEN immunohistochemistry (IHC) has been suggested as potentially the most accurate reflection of functional PTEN status. (8) The P53 protein is involved in gene transcription, DNA synthesis and repair, genomic plasticity, and apoptosis. (6, 7) Mutation of P53 is commonly observed in serous papillary endometrial carcinomas, as well as 10-15% of early and 40-50% of advanced endometrioid endometrial carcinomas. (7) Its identification is associated with poor prognosis. (9) In this study we aim to analyze the PTEN and p53 gene immunoexpression in cases of endometrioid and serous papillary endometrial carcinoma, and correlate the PTEN and p53 expressions with tumor grade and disease stage.

## 2 | AIMS AND OBJECTIVES:

Our aim is to study the incidence of proliferative endometrial changes in peri and post menopausal women and evaluate the immuno expression of PTEN and P53 genes and correlate their expression with prognostic outcomes in cases of endometrial carcinoma.

## 3 | MATERIAL AND METHODS:

It is a prospective and observational study conducted at the Institute of Post Graduate Medical education and research, Kolkata, over a period of 18 months. Total 60 patients, in the peri menopausal and post menopausal age group with abnormal uterine bleed were thoroughly evaluated in the Gynecology department. As per radiological findings small biopsy

**Supplementary information** The online version of this article (<https://doi.org/10.15520/jcmro.v3i08.321>) contains supplementary material, which is available to authorized users.

**Corresponding Author:** Dr. Ayesha Afreen Islam  
Demonstrator, Department of Pathology, Institute of Post Graduate Medical Education and Research  
Email: [annie28dec85@gmail.com](mailto:annie28dec85@gmail.com)

## STUDY OF PROGNOSTIC AND DIAGNOSTIC SIGNIFICANCE OF P53 AND PTEN MUTATION IN PROLIFERATIVE LESIONS OF ENDOMETRIUM

or hysterectomy samples were received at the department of pathology for histopathological examination. Cases diagnosed as endometrial carcinoma were further studied for gene expression of PTEN and P53 by using immunohistochemistry markers.

For statistical analysis, p value was estimated using the ANOVA test.

### 4 | RESULTS:

Sixty patients (60) were selected in the peri menopausal and post menopausal age group. The mean age for hyperplastic lesions was 44.9 years and for carcinoma, 53.2 years. The most common chief complaint was abnormal uterine bleeding (70%), followed by pain and lump in the abdomen. Associated co-morbidities like hypertension (42%) diabetes (38%) and obesity (28%) were observed in the patient cohort. Transvaginal Ultra sonography showed that 89% patients had endometrial thickness of  $\geq 5$ mm. For histopathological examination 30(50%) specimens were of abdominal hysterectomy, and 30 specimens were of endometrial biopsies. On HP examination we found 35% were endometrial hyperplasia and 65% of cases were endometrial carcinoma.

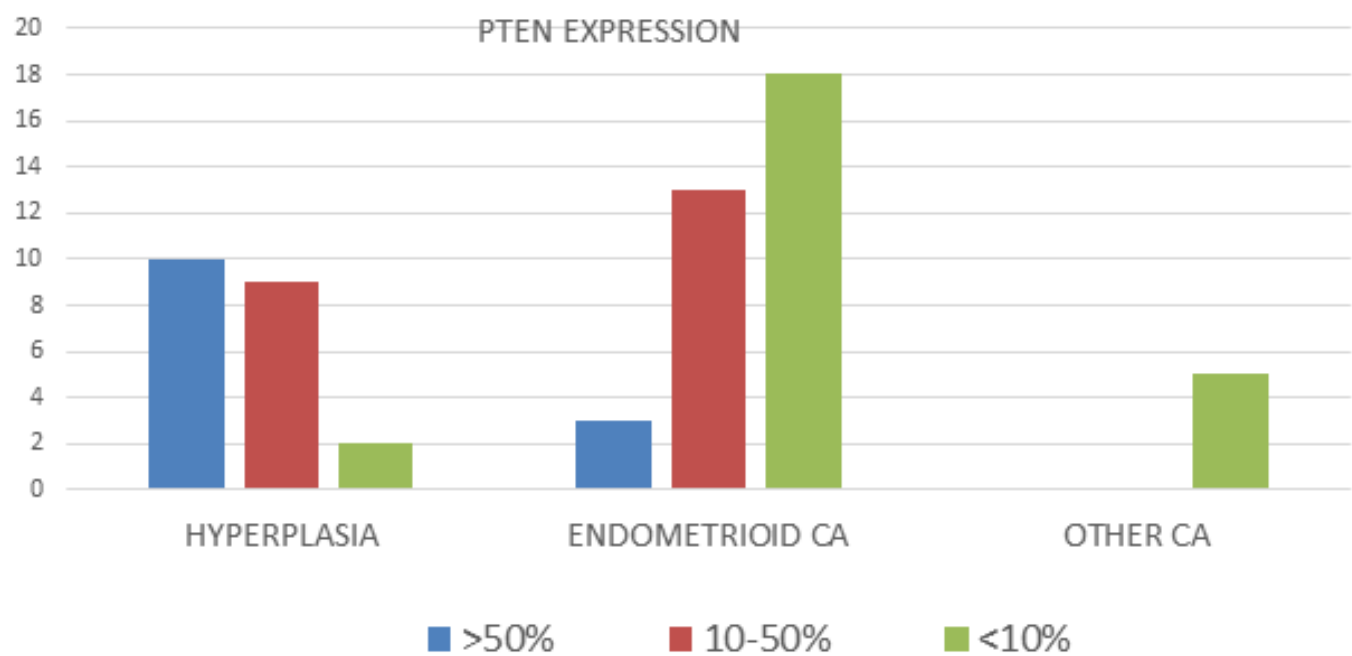
Among the endometrial hyperplasia cases, 76% were endometrial hyperplasia with atypia and 24% cases were hyperplasia without atypia. Among the carcinoma cases, 87% were of endometrioid type and 13% were of other types, which included serous, clear cell type and malignant mixed Mullerian type of carcinoma. Histological parameter like tumor grade, myometrial invasion, cervical invasion and vascular invasion were assessed in cases of carcinoma. Eighteen (53%) were grade 3 tumors, 11 (32%) were grade 2 and 5(15%) were grade 1. Myometrial invasion was found in 29 cases out of which 4 cases showed  $<1/2$  and rest showed  $>1/2$  of myometrial invasion. Cervical invasion is present in 14 cases. Vascular invasion was found in 10 cases. IHC study was done for PTEN and P53. PTEN expression was higher in endometrial hyperplasia than endometrial carcinoma

cases Figure 1. Loss of PTEN expression is found to be an indicator of endometrial carcinoma. P53 over expression was found in 3 cases (5%) endometrioid endometrial carcinoma and 6 cases (8.3%) of other variants of endometrial carcinoma. Figure 2 P53 was found to be in more in cases with FIGO staging III & IV compared to stage I & II (100% vs 18.1% p value= 0.0016) and grade 3 compared to grade 1&2 (50%vs 0 p value= 0.0116) Table 1. Other variants like serous, clear cell type and malignant Mullerian mixed tumor showed higher expression of P53 suggesting earlier event in these rare tumor. In our study we found that P53 elevated expression correlated with poor differentiation of endometrial cancer.

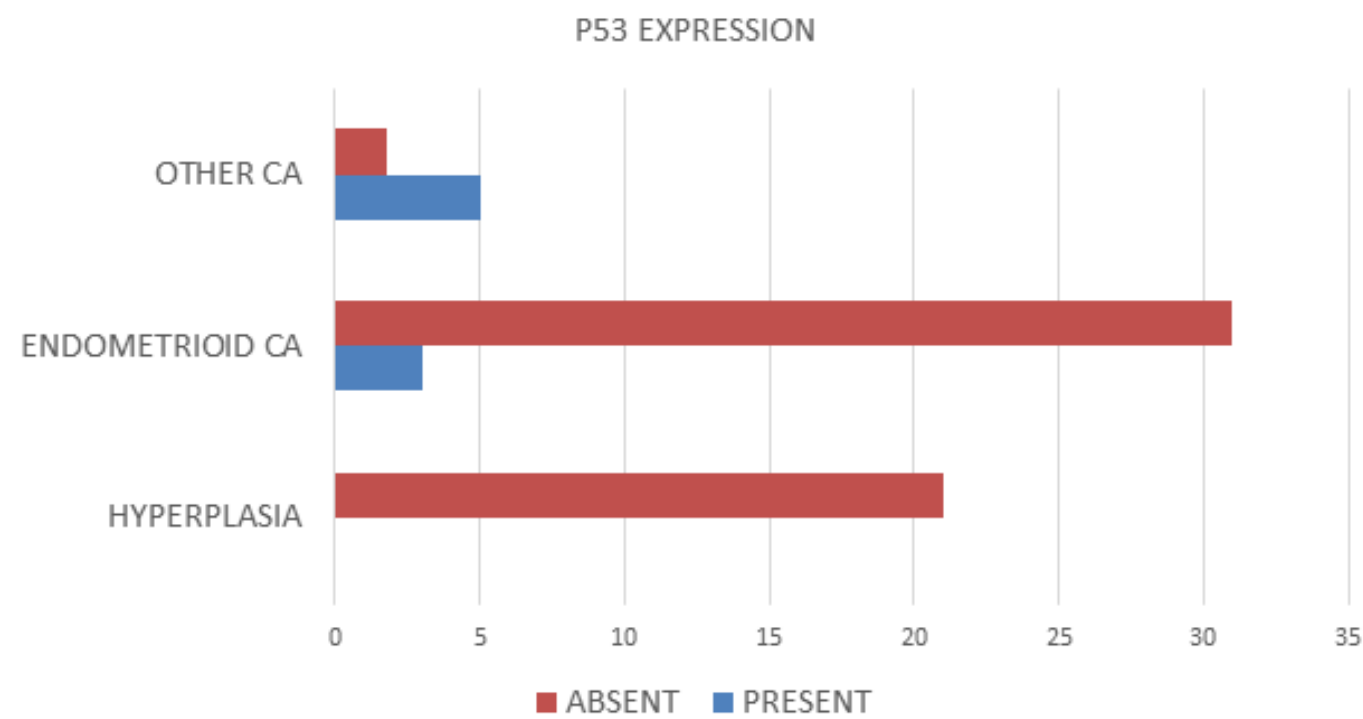
The correlation of the biomarkers with the prognostic parameters in cases of endometrial carcinoma has been summarized in Table 1.

### 5 | DISCUSSION:

Can et al in their 2019 study found that the average age in the patient group (n=20) was 55.35 yrs. In the patient group (total 60 cases), it was observed that 7 of the patients had grade 1 endometrioid adenocarcinoma (35%), 7 of them had grade 2 endometrioid adenocarcinoma (35%) and 6 of them had grade 3 endometrioid adenocarcinoma (30%). (10) In our study the mean age in carcinoma patients was found to be 53.2 years. Also in our study 18(53%) are grade 3 tumors, 11(32%) are grade 2 and 5(15%) were grade 1 endometrial carcinomas. Can et al also found that P53 expression in all of the Grade1, Grade2 and Grade3 patients increased significantly (p=0.000). (10) In our study P53 was found to be in more no of cases with FIGO staging III & IV compared to stage I & II (100% v/s 18.1% p value= 0.0016) and grade 3 compared to grade 1&2 (50% v/s 0 p value= 0.0116). Kholy et al in 2018 studied a total of 40 cases, 22 (55%) cases of endometrial hyperplasia and 18 (45%) cases of EC. The cases were distributed as follows: simple hyperplasia (25%), complex hyperplasia (15%), atypical hyperplasia (15%), and Endometrial carcinoma (45%). In our study 35% were endometrial hyperplasia and 65% of cases were endometrial carcinoma. Among the



**FIGURE 1:** :PTEN expression (n=60) (PTEN: Staining of cells was reported as 0 if <10%,of tumor area was positive.



**FIGURE 2:** P53 expression (n=60): Samples showingnuclear staining at least 20% of cells is considered to be positive.

# STUDY OF PROGNOSTIC AND DIAGNOSTIC SIGNIFICANCE OF P53 AND PTEN MUTATION IN PROLIFERATIVE LESIONS OF ENDOMETRIUM

**TABLE 1:** Correlation of biomarkers with prognostic parameters.

Characteristics	No of patients	PTEN(Positive) >10%	P53(Positive) >20%	Ki67(positive) >40%
All endometrial Cancer patient	39(%)			
Age - >65 yrs	03(7.7)	02(66.6)	0	03(100)
Age-<65yrs	36(92.3)	14(38.8)	09(25)	09(25)
P value		0.5	1	0.024
FIGO I & II	34	17(50)	0	17(50)
FIGO III & IV	05	0	05(100)	05(100)
P value		0.05	<0.0001	0.05
Grade 1&2	16	15(93.7)	0	15(93.7)
Grade 3	23	02(8.6)	04(17.3)	23(100)
P value		<0.0001	0.12	0.41

endometrial hyperplasia, cases with atypia and cases without atypia were 76% and 24% respectively. (11) Schultheis et al in 2016 found that among the 228 Serous and Endometrioid ECs included in this study, 64 (28%) harbored a mutation in TP53. (12) A comparative analysis of TP53 mutations according to histological types revealed that Serous ECs are significantly more frequently TP53-mutant than Endometrioid ECs (88% vs. 15%, respectively; Fisher's exact test  $p < 0.0001$ ). TP53-mutant ECs had a significantly worse overall survival than TP53 wild-type cancers. In this dataset of 228 Endometrial Carcinomas, ARID1A and PTEN were significantly more frequently mutated in Endometrioid type ECs (ARID1A, 39% EEC vs. 10% SECs; PTEN, 78% EECs vs. 2% SECs; (Fisher's exact test  $p < 0.001$ ). It was observed that within the group of TP53-mutant Endometrial carcinomas, somatic mutations affecting PTEN are significantly more frequently found in Endometrioid type ECs than in Serous ECs. (12) Koley et al also found in their study that PTEN expression among the patient groups, decreased in atypical hyperplasia (50%) and EC (27.8%) than simple hyperplasia (70%) and complex hyperplasia (83.3%). Regarding the cases of EC, the expression of PTEN decreased in high-grade tumors: 42.9% in grade I, 20% in grade II and 16.7% in grade III. (11) In our study we found that PTEN expression was significantly higher in endometrial hyperplasia as compared to endometrial carcinoma. Grade 1 and 2 endometrial carcinomas showed PTEN positive

expression as compared to grade 3 tumors (93.7% v/s 8.6%,  $p < 0.0001$ ). The obtained results indicate that the mutations occurring in PTEN gene and the inactivity of PTEN gene are effective in the early stages of endometrioid adenocarcinoma pathogenesis, as they are effective in estrogen-dependent endometrial carcinomas. (10, 12) Another important reason why the PTEN expression loss is more important in endometrial carcinogenesis compared to conditions observed in other malignancies is that it can be diagnosed in earlier stages of FIGO staging and thus, it enables early diagnosis and decreases in morbidity rate. (13) Ellenson et al in 2019 observed that the missense mutations were found to correlate with intense, diffuse immuno histochemical staining for p53; by contrast, a complete lack of staining (null pattern) for p53 was indicative of nonsense or frame shift mutations. (13) Stavropoulos et al in 2019 studied retrospective immuno histochemical analysis of the expression of p53 and PTEN tumor suppressor proteins in 99 women with endometrial carcinoma. The overall rate of p53 and PTEN positivity was 89 and 77%, respectively, according to the sum of stain intensity and scores of immuno positive cells. (14) The sum of p53 positivity correlated strongly with PTEN expression ( $\rho = 0.256$ ;  $P = 0.044$ ). The concomitant sum of p53 and PTEN expression was identified in 45% of patients with endometrial adenocarcinoma. The sum of the immuno histochemical expression of p53 significantly correlated with patient age ( $P = 0.037$ ), histological



type ( $P=0.008$ ), histological grade ( $P=0.002$ ) and fallopian and/or ovarian invasion ( $P=0.014$ ). Furthermore, PTEN expression was associated with myometrial invasion ( $\rho=-0.377$ ;  $P=0.002$ ) and clinical stage ( $P=0.019$ ). (14) Thus, p53 immunohistochemistry became a widely used diagnostic tool to support the diagnosis of serous carcinoma in the appropriate setting. The presence of TP53 mutations in SEIC (The precursor lesion, termed serous endometrial intra epithelial carcinoma (SEIC), supports the idea that TP53 mutation is an early driver of serous carcinoma development. (13, 14) Elwy et al. in 2016 found that PTEN immuno reactivity was noted in all normal proliferative and hyperplastic endometrium, whereas 80% of Endometrioid type ECA showed complete absence or diminution of PTEN expression. (15–18)

## 6 | CONCLUSION:

The present study suggests a strong correlation between the expression of p53 and PTEN in endometrial

Adenocarcinoma, indicating an intrinsic association between the expression of these tumor suppressor genes. In addition, correlation of mutation status with the age of patients and the histological differentiation, it is noted that concomitant p53 and PTEN expression may contribute to the characterization of tumor behavior in endometrial carcinomas. Further, this study demonstrates the altered activity of certain genes during different cancer stages and that the survival rates of patients with endometrial carcinoma could be predicted using the set of genes investigated.

## REFERENCES

1. Bansal, N., Yendluri, V., & Wenham, R. M. (2009). The molecular biology of endometrial cancer and the implications for pathogenesis, classification and targeted therapies. *Cancer Control* January, 16, 8-13.
2. Kapucuoğlu, N., Aktepe, F., Kaya, H., Bircan, S., Karahan, N., Çiriş, M. (2007). Immunohistochemical expression of PTEN in normal, hyperplastic and malignant endometrium and its correlation with hormone receptors, bcl-2, bax, and apoptotic index. *Path. Res. and Prac.*, 3, 153-162.
3. D. Llobet, J. Pallares, A. Yeramian, et al., "Molecular pathology of endometrial carcinoma: practical aspects from the diagnostic and therapeutic viewpoints," *Journal of Clinical Pathology*, vol. 62, no. 9, pp. 777–785, 2009
4. T. T. Nieminen, A. Gylling, W. M. Abdel-Rahman, et al., "Molecular analysis of endometrial tumorigenesis: importance of complex hyperplasia regardless of atypia," *Clinical Cancer Research*, vol. 15, no. 18, pp. 5772–5783, 2009
5. Rivlin N, Brosh R, Oren M, et al. Mutations in the p53 Tumor Suppressor Gene: Important Milestones at the Various Steps of Tumorigenesis. *Genes Cancer*. 2011; 2:466–74.
6. McConechy MK, Ding J, Cheang MC, et al. Use of mutation profiles to refine the classification of endometrial carcinomas. *J Pathol*. 2012; 228:20–30.
7. Hoang LN, McConechy MK, Kobel M, et al. Histotype-genotype correlation in 36 high-grade endometrial carcinomas. *Am J Surg Pathol*. 2013; 37:1421–32.
8. Garg K, Broaddus RR, Soslow RA, Urbauer DL, Levine DA, Djordjevic B. Pathological Scoring of PTEN Immunohistochemistry in Endometrial Carcinoma is Highly Reproducible. *Int J Gynecol Pathol*. 2012 January ; 31(1): 48–56.

# STUDY OF PROGNOSTIC AND DIAGNOSTIC SIGNIFICANCE OF P53 AND PTEN MUTATION IN PROLIFERATIVE LESIONS OF ENDOMETRIUM

9. Dedes KJ, Wetterskog D, Ashworth A, Kaye SB, Reis-Filho JS. 2011. Emerging therapeutic targets in endometrial cancer. *Nat. Rev. Clin. Oncol.* 8:261–71.
10. Can NK, Mesut C, Kurtulmuş Y. The Immunohisto Chemical Examination of Changes that Take Place in PTEN Expression in Endometrioid Adenocarcinomas. *Int J of Health Sciences.* 2019;3:69-77.
11. Kholi MA, Kholi EA. Endometrial hyperplasia versus carcinoma: does phosphatase and tensin homolog immunohistochemical expression differentiate between them. *Sci J Al-Azhar Med Fac, Girls* 2018; 2:150–155.
12. Schultheis AM, Martelotto LG, Filippo MRD, Piscuoglio S, Charlotte K, Hussein YR et al. TP53 Mutational Spectrum in Endometrioid and Serous Endometrial Cancers. *Int J Gynecol Pathol.* 2016 ; 35(4): 289–300.
13. Ellenson LH, Bell DW. Molecular Genetics of Endometrial Carcinoma. *Annu. Rev. Pathol. Mech. Dis.* 2019. 14:339–67.
14. Stavropoulos A, Varras M, Vasilakaki T, Varra VK, Tsavari A, Varra FN et al. Expression of p53 and PTEN in human primary endometrial carcinomas: Clinicopathological and immunohistochemical analysis and study of their concomitant expression. *Oncology Letters* 2019; 17: 4575-89.
15. Elwyet DA, Abd Al-Aziz AM, El Sheikh SA, Darweesh MF, Dina F. Elyasergy: expression of PTEN in endometrioid carcinoma, istopathological and immunohistochemical study. *World J Med Sci* 2016;13:118–125
16. Althubiti MA. Mutation frequencies in endometrial cancer patients of different ethnicities and tumor grades: An analytical study. *Saudi J Med Med Sci* 2019;7:16-21.
17. Samarntai N, Hall K, Yeh I. Molecular Profiling of Endometrial Malignancies. *Obstetrics and Gynecology International* 2010;10:1-16.
18. Esmaili HA, Amidfar H, Mostafidi E, Amidfar A. Study on the prognostic value of p53 and PTEN immunomarkers for endometrial cancer using immunohistochemistry. *J Anal Res Clin Med* 2017;5(4): 112-7.

**How to cite this article:** Ray, S., Jha, A., Afreen Islam, A., & Sengupta, M. (2020). Study of prognostic and diagnostic significance of P53 and PTEN mutation in proliferative lesions of endometrium. *Journal of Current Medical Research and Opinion*, 3(08).  
<https://doi.org/10.15520/jcmro.v3i08.321>