



Case Report

Frontal Skin Metastasis from Undifferentiated Carcinoma of Nasopharynx: A Case Report

Yahia Mohammedi ¹, Assia Abdi ², Yassine Merad ³

¹Mostaganem ENT department, University of Mostaganem

²Anatomopathology department, University of Mostaganem

³Central laboratories, University Djilali Liabes, Sidi-Bel-Abbes

Abstract

Cutaneous metastasis in nasopharyngeal carcinoma is a rare entity but carries a poor prognosis, reflecting an advanced phase of the disease. The most frequent metastatic sites are located in the head and neck region, while frontal involvement is exceedingly uncommon. We report the case of a 56-year-old woman with no significant medical history who was diagnosed four years earlier with undifferentiated carcinoma of the nasopharyngeal type (UCNT). The patient underwent concomitant radiochemotherapy, achieving complete remission for three years, then the patient was lost to follow-up for two years and later presented with recurrent nasal obstruction and a frontal cutaneous lesion, initially nodular and subsequently ulcerated. Endoscopic and radiological evaluation, along with biopsy, confirmed recurrence of nasopharyngeal carcinoma with nodal metastasis and frontal cutaneous metastasis. The patient was referred to oncology for second-line treatment.

Keywords: Nasopharynx, Carcinoma, Undifferentiated Carcinoma, Skin Metastasis

Introduction

The skin, as the largest organ of the human body, can occasionally serve as a site for metastatic dissemination from internal malignancies such as head and neck carcinomas, breast carcinoma, and neuroendocrine tumors. Cutaneous metastatic involvement may occur via hematogenous or lymphatic pathways or through direct invasion from adjacent anatomical structures, resulting in cutaneous metastatic carcinoma. Despite these potential pathways, cutaneous metastasis (CM) remains a relatively rare clinical presentation^{1,2,3}.

Nasopharyngeal carcinoma (NPC) is a malignant epithelial neoplasm originating from the mucosal lining of the nasopharynx. According to the International Agency for Research on Cancer, approximately 129,000 new cases were described in 2018, comprising only 0.7% of all malignancies^{4,5}. CM originating from NPC is exceptionally uncommon. The present case describes a rare case of frontal skin metastasis a patient with a NPC, in whom dermatological manifestations and histopathological assessment were critical for establishing the diagnosis.



Corresponding Author: Yassine Merad, Central laboratories, University Djilali Liabes, Sidi-Bel-Abbes.

E-mail: yassinemerad8@gmail.com



©Copyright 2026 The Current Medical Research and Opinion. Licenced by Creative Commons Attribution-Non Commercial-NoDerivatives (CC BY-NC-ND) 4.0 International License. (<https://creativecommons.org/licenses/by-nc-nd/4.0/>).

Received: 10.11.2025 | Revised: 29.12.2025 | Accepted: 09.01.2025 | Published: 15.01.2026

Case report

We describe a 56-year-old female patient, non-smoker, with no significant past medical history, who had been treated in 2020 for an undifferentiated nasopharyngeal carcinoma with concomitant radiochemotherapy, and subsequently lost to follow-up after the last treatment cycle. She presented to the ENT department in May 2025 with nasal obstruction, epistaxis, and right cervical and parotid lymphadenopathy, without associated neurological signs. Clinical examination also revealed a left frontal supraciliary ulcerated skin lesion Figure 1, initially nodular according to the patient, which had progressively ulcerated and been neglected.

Endoscopic evaluation showed a mass completely obstructing the right choana and partially obstructing the left choana. MRI of the nasopharynx and facial structures demonstrated a locoregional recurrence occupying the entire nasopharynx, extending toward the soft palate and into the sphenoid sinus, associated with cervical and parotid lymphadenopathy. Thoracoabdominal CT revealed pulmonary nodules suspicious for metastatic disease Figure 2. Nasofibroscopy-guided biopsy confirmed an undifferentiated nasopharyngeal carcinoma. Bone scintigraphy was unremarkable. Biopsy of the frontal skin lesion was consistent with cutaneous metastasis of an undifferentiated nasopharyngeal carcinoma.

The case was discussed in a multidisciplinary tumor board, and second-line chemotherapy was recommended.

Discussion

We report a very rare case of a frontal cutaneous metastasis occurring during the recurrence of an undifferentiated nasopharyngeal carcinoma. Very few cases of cutaneous metastasis from nasopharyngeal UCNT have been described in the literature^{1,2}, and frontal involvement is even more uncommon. In the literature, cutaneous metastasis corresponds to the development, within the skin, of a malignant tumor originating from a distant primary site. It may constitute the first revealing sign of an underlying cancer or the first sign of

metastatic recurrence of a previously treated malignancy, as shown in our case⁴. The cancers most frequently associated with cutaneous metastases are breast, colorectal, and lung cancers^{6,7}. Cutaneous metastases from head and neck cancers particularly nasopharyngeal carcinoma are extremely rare, accounting for less than 1% of cases, and are associated with a relatively poor prognosis². The precise mechanism underlying cutaneous metastasis remains poorly understood. Several hypotheses have been proposed to explain the pathways of dissemination. Distant cutaneous metastases appear to spread primarily via the hematogenous route, whereas local metastases may disseminate through dermal lymphatic pathways or result from iatrogenic manipulation leading to tumor cell implantation^{8,9}. There is no standardized therapeutic method for cutaneous metastases. Given the highly unfavorable prognosis and the metastatic nature of the disease, treatment is generally palliative. The prognosis remains poor, with a median survival ranging from 3 to 7 months⁹.

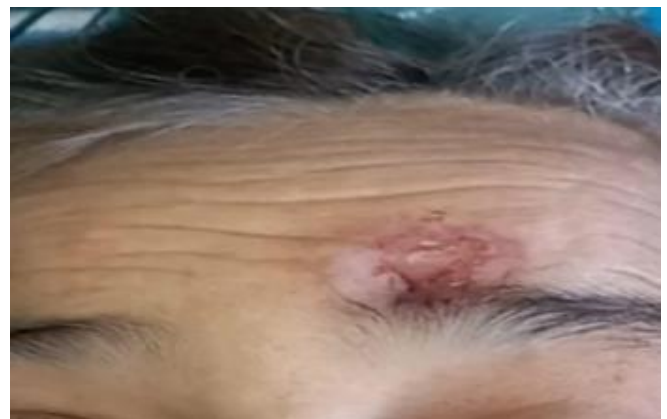

Figure 1: Frontal skin metastatic lesion

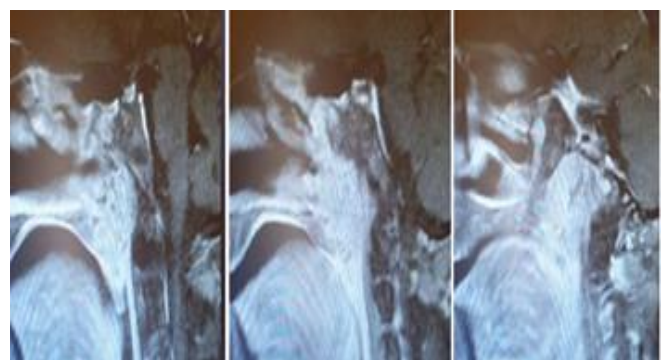


Figure 2: MRI image of the nasopharyngeal tumor

Conclusion

Cutaneous metastases may represent the first revealing sign of metastatic relapse of nasopharyngeal carcinoma. Given their poor prognosis, the likelihood of cutaneous metastasis should always be considered when evaluating skin lesions in patients with a history of cancer

Conflicts of interest

The authors disclose no conflict of interest.

Acknowledgments

Some special thanks go to everyone who contributed to this research work, particularly the staff of the ENT department of the university hospital of Mostaganem

Funding

This research received no specific funding from funding agencies

References

1. Ferlay J, Soerjomataram I, Ervik M, Dikshit R, Eser S, Mathers C et al. GLOBOCAN 2012: estimated cancer incidence, mortality and prevalence Worldwide in 2012 v1.0:IARC CancerBase No11. 2012.
2. Kmucha ST, Troxel JM. Skin metastases from head and neck squamous cell carcinoma: incidence and impact Head & Neck. Head Neck. 1999 Sep;21(6):560-5.
3. Merad Y, Belmokhtar Z, Messafeur A et al. Prevalence of superficial mycosis in breast cancer patients : a cross-sectional study. Cancer Science research, 2(4), 1-4, 2019
4. Emanuel H, Emanuel P. Cutaneous Metastasis of Head and Neck Malignancy. Int J Head Neck Surg. 2015;6(2):57-63.
5. Lookingbill DP, Spangler N, Helm KF. Cutaneous metastases in Vinita Trivedi, Muneer Abdul khalam, Manashi Ghosh, Richa patients with metastatic carcinoma: a retrospective study of 4020 patients. J Am Acad Dermatol. 1993 ;29(2 Pt 1):228-236.
6. Wollina U, Graefe T, Konrad H, Schönlebe J, Koch A, Hansel G et al. Cutaneous metastases of internal cancer. Acta Dermatoven APA. 2004; 13(3): 79-84.
7. Modugumudi Ananta Satya Narayana, Rashmi Patnayak, Nandyala Rukmangadha, Amit Kumar Chowhan, Radhika Kottu, Bobbidi Venkatesh Phaneendra. Cutaneous metastasis of transitional cell carcinoma of the urinary bladder: Cytological aspect. J Cytol. 2014 Jan-Mar; 31(1): 50-52.
8. Chauhan, Syeda Naseera. An exceptional case of cutaneous metastasis of squamous cell carcinoma of the lip. Journal of Cancer Research and Practice. December 2017; 4(4): 156-158.
9. Raj Nagarkar, Ashvin Wagh, Gauri Kokane, Mayank Patil, Aditya Markanday. Incidence and Prognostic Factors in Distant Metastasis from Primary Head and Neck Cancer-An Institutional Experience. J Head Neck Spine Surg J. 2017; 1(5): 555571.