

**CASE STUDY**



## Intermediate-Grade Neuroendocrine Mediastinal Tumor a 38-Years- Old Man: Case Report and Literature Review

Milián-Saavedra Lucía Vanessa<sup>1</sup> | Martínez-Castro Luis Roberto<sup>1</sup> | Sánchez-Tun Jimy Agustín<sup>2</sup> | Naranjo-Cruz Alondra Yereldi<sup>3</sup> | Jiménez-Báez María Valeria<sup>4\*</sup>

<sup>1</sup>Medical Intern of Social Service. General Hospital Regional No. 17. Mexican Institute of Social Security. Quintana Roo.

<sup>2</sup>Medical Intern of Social Service. Family Medicine Unit No. 15. Mexican Institute of Social Security. Quintana Roo.

<sup>3</sup>Oncology Department. General Hospital Regional No.17 Mexican Institute of Social Security. Quintana Roo

<sup>4</sup>Head of Medical Benefits Services. Coordinator of Institutional Planning and Liaison. Mexican Institute of Social Security. Quintana Roo



### Abstract

**Introduction.** Neuroendocrine tumors of the mediastinum (MNET) are rare. They represent 0.4% of all carcinoid tumors and 5% of all anterior mediastinal masses.

**Clinical case.** A 38-year-old man has chest pain, dyspnea on moderate exertion, insomnia, hip pain, nausea and cough, jugular engorgement, plethoric faces, venous network in the thorax. The final diagnosis was intermediate-grade neuroendocrine mediastinal tumor with vena cava syndrome. He was not a candidate for surgery, so he continued medical management with radiotherapy and chemotherapy. He developed spinal syndrome and, finally, heart failure secondary to carcinoid syndrome and chemo toxicity.

**Discussion:** The most common signs are respiratory manifestations, and in some cases, they begin with superior vena cava syndrome. Computerized tomography (CT), magnetic resonance imaging (MRI), immunohistochemistry with chromogranin A and synaptophysin establish the diagnosis. The therapy prescript is surgical resection and systemic therapy with neoadjuvant chemotherapy comprising cytotoxic drugs such as cisplatin/carboplatin as the ideal treatment. New therapies such as Peptide Receptor Radionuclide are helpful for extensive tumors, like systemic chemotherapy based on <sup>177</sup>Lu-Dotatate. It is a neoplasm of difficult diagnosis and bad prognosis; with timely treatment, patients have a better quality of life.

**Abbreviations:** MNET (Mediastinal Neuroendocrine Tumor), ECOG (Eastern Cooperative Oncology Group), CgA (Chromogranin A).

**Keywords:** Mediastinum, Neuroendocrine tumor, Surgery, Radiotherapy, Chemotherapy.

**Copyright :** © 2021 The Authors. Published by Publisher. This is an open access article under the CC BY-NC-ND license (<https://creativecommons.org/licenses/by-nc-nd/4.0/>).

## 1 | INTRODUCTION

The mediastinum is a cavity that originates in the fourth week of gestation from embryonic layers. The seventh week completes its development when the pleuropericardial membrane fuses with the ventral mesoderm of the esophagus (1). The sternum and the vertebral bodies bound this structure. It separates the two pleural spaces, limited by the upper thoracic aperture and the diaphragm; inside it contains heart, lungs, and others structures (1, 2). The masses in the mediastinum are rare and cover a wide spectrum (3).

The neuroendocrine tumor cells are similar to the serotonergic neurons; they contain a dense nucleus that stores monoamines, still without synapsis function, and have an endocrine component that can synthesize and secrete monoamines (4). These cells distribute in most body organs, and the most common presentation places are respiratory and gastrointestinal tracts (5–7) (8). They represent 25% of all primary lung neoplasms and 1–2% of all invasive lung malignancies (5). MNET is an infrequent clinical entity that reports 0.4% of all the carcinoid tumors and 5% of all the masses in anterior mediastinum (9). MNET's demonstrate male predisposition with a male-to-female ratio of approximately 3:1 and have been enormously controversial in the literature due to the debate about the origin, terminology, and classification (5–9).

The World Health Organization (WHO) in 2015 proposed the classification of tumors in organs such as lung, pleura, thymus, and heart provides diagnostic criteria for MNET's based on histopathologic characteristics, cellular morphology, mitotic count, tumor necrosis, and immunohistochemical markers such as chromogranin A, synaptophysin, and CD56 (5–9). MNET's classification divides into high-grade malignant neoplasms, small cell carcinoma and large cell carcinoma, typical low-grade carcinoid, and intermediate-grade adenocarcinoma (5–9).

The purpose of the article is to present a case report of an intermediate-grade mediastinal neuroendocrine tumor diagnosis in a 38-years-old man after reviewing the medical literature.

## 2 | CASE PRESENTATION

The case is about a 38-year-old man allergic to ketorolac. In February 2016, He began with chest pain, hips pain, dyspnea, insomnia, nausea, and cough. The chest radiography reports a mass in the mediastinum Figure 1<sup>(Figure1A)</sup>; the contrasted chest tomography revealed a heterogeneous tumor in close contact with the right atrium Figure 1<sup>(Figure1B)</sup>, trucut needle puncture biopsy reported small round cell neoplasm, immunohistochemical study with chromogranin A and synaptophysin expression positive, ki 67 of 5%, negative tumor markers.

The final diagnosis was intermediate-grade neuroendocrine mediastinal tumor with superior vena cava syndrome.

The patient wasn't a candidate for surgical resection, so radiotherapy started in April 2016 with 25 sessions. In July of the same year, he received first-line chemotherapy with etoposide and cisplatin (6 cycles). A significant reduction was observed, with a partial radiographic response (22% decrease in tumor measurements by RECIST) (10) in the six months after the beginning of therapy.

In 2017, he progressed to second-line chemotherapy with capecitabine and temozolomide (8 cycles). A control contrasted chest tomography reports a heterogeneous lesion in mediastinum measuring 72x126x110mm and multiple nodular lesions Figure 2.

in February 2018, the patient got hospitalized due to a mitral and tricuspid regurgitation valve. Heart failure secondary to carcinoid syndrome and extrinsic compression of the mediastinal tumor. During this period, he presented physical deterioration with

---

**Supplementary information** The online version of this article (<https://doi.org/10.15520/jcmro.v4i06.428>) contains supplementary material, which is available to authorized users.

---

**Corresponding Author:** Jiménez-Báez María Valeria

Head of Medical Benefits Services. Coordinator of Institutional Planning and Liaison. Mexican Institute of Social Security. Quintana Roo  
Email: [Valeria.jimenezb@gmail.com](mailto:Valeria.jimenezb@gmail.com)

## INTERMEDIATE-GRADE NEUROENDOCRINE MEDIASTINAL TUMOR A 38-YEAR- OLD MAN: CASE REPORT AND LITERATURE REVIEW

a score of 2 on the ECOG scale (Eastern Cooperative Oncology Group) (11). He started third-line chemotherapy with octreotide 40 mg combined with diuretics, digoxin, and atorvastatin. One month later, he referred to paresis and dysesthesia in the lower limb and loss of sphincter control, for which an MRI requires Figure 3<sup>(Figure3A–B)</sup> that reported metastases in the lumbar spine. He underwent palliative radiotherapy with clinical improvement, but he did not conclude all the sessions because he presented orthopnea, lost mobility in the lower extremities. He progressed to fourth-line chemotherapy with dacarbazine/epirubicin with symptomatic recovery.

In April 2019, due to disease progression and the deteriorated functional status (ECOG 3), (11) started palliative treatment based on opioid analgesic and zoledronic acid. He eventually developed heart failure secondary to carcinoid syndrome and chemotoxicity after receiving four lines of therapy.

### 3 | METHODOLOGY

A medical literature review was done through the systemic consultation of scientific documents and studies. It defines the following objectives to help explore the search and synthesis of evidence:

1. Identify information necessary to analyze the clinical case addressed on the mediastinal neuroendocrine tumor.
2. Determine the best practice in the diagnosis and treatment of mediastinal neuroendocrine tumors.

**Search strategy:** It was employed a simple search strategy to locate studies defining comparisons, evaluations, methodological approaches, and impact. The keywords were "Mediastinal neuroendocrine "tumor/pathology, "Mediastinal "tumors/classification, "Mediastinal "tumors/epidemiology. "Mediastinal tumors / diagnosis". "Mediastinal tumors / treatment". The terms search used include the recognized medical subject title (MESH): ("Neuroendocrine Tumors/physiopathology" [Mesh]) and [Mesh]OR

"NeuroendocrineTumors/therapy" [Mesh]. Pubmed, Elsevier, EMBASE and Health Virtual Library (LILACS), New Journal England of Medicine, Journal of the American Medical Association (JAMA) conducted Electronic searches. It imposed publication date restriction with a range of 5 years old to the current year (2017-2021).

**Selection criteria for literature:** The inclusion criteria were meta-analysis type scientific articles, systematic review, case-control studies, and analysis of clinical cases, which reported experiences, epidemiology, etiology, pathology, diagnosis, and treatment of mediastinal neuroendocrine tumor; ethical guidelines used in clinical cases to interpret the evidence from the studies—published studies written in English, Spanish and French. In addition, those articles that met the criteria of the PRISMA methodology selects. Studies with a range lower than 2017 exclude and those that did not have at least one PRISMA type format.

**Search Results:** The Initial electronic searches identified 866 articles. From these articles, titles, and abstracts reviews, of which 121 required a full review. The 45 full articles examined, 30 studies were similar to the clinical case, and 22 met the inclusion criteria Figure 5<sup>(Diagram1)</sup>.

### 4 | DISCUSSION

The clinical picture of mediastinal neuroendocrine tumors is varied. However, there is a percentage of patients who are asymptomatic (12), and retrosternal pain is the most common manifestation (9). Respiratory manifestations are dry cough, inspiratory dyspnea, mainly (9, 12).

The vena cava syndrome is characterized by a gradual compression of vena cava, produce edema and retrograde blood flow. There are trigger symptoms such as cough, dyspnea, dysphagia, edema, or discoloration of the neck, face, and upper extremities (13). In this case, the patient begins with a similar clinical picture of gradual onset characterized by cough, dyspnea, and edema.

Current diagnostic methods include computed tomography and magnetic resonance imaging. In these tumors with many variabilities, any study modality is completely effective alone. When they are together, present a sensitivity > 90% and a specificity of 92-98% (14). Incidental findings through chest radiography have been reported (13, 15). The computed tomography determines the size, extension, relationship with adjacent structures, and local invasion or metastasis, allowing a close differential diagnosis and treatment planning (12, 15).

Magnetic resonance imaging has more utility in case to view the tumor growing and vascular or cardiac invasion (5).

In this case, we reach the diagnosis of spinal cord syndrome by RMI. The definitive diagnosis with pathological identification by biopsy and positivity of the specific markers (12, 13).

The specific immunohistochemical markers for neuroendocrine tumors are Chromogranin A (CgA). It has a sensitivity of 91% and specificity > 90%.

It with Synaptophysin has a sensitivity of 60-90% (15, 16).

Both elevate at the time in this case, the diagnostic criteria were met in all the studies carried out.

There aren't standard treatments yet, but surgical resection has been considered a curative alternative (14, 17), which could not be performed due to the size of the tumor and its contact with the superior vena cava and right atrium.

The systemic therapy, with curative and neoadjuvant objectives, includes cytotoxic drugs such as cisplatin/carboplatin and etoposide or streptozocin and 5-fluorouracil, mainly in cases where the tumor in an advanced stage already invades thoracic structures, this to reduce the tumor burden and make the tumor susceptible for surgery or alternative therapy (12, 13).

A case of large cell mediastinal neuroendocrine carcinoma reported that was successfully treated with systemic chemotherapy after palliative radiotherapy (18). In this case, he was treated with 4 lines of chemotherapy, starting with etoposide and cisplatin as recommended in the literature, which decreased the size of the tumor, but it was still unresectable.

There are new strategies such as Peptide Receptor Radionuclide Therapy (PRRT) which is systemic chemotherapy based on <sup>177</sup>Lu-Dotatate that has shown greater utility in reducing extensive tumors (19, 20). In a retrospective analysis from Minnesota of a series of 11 patients with thymic neuroendocrine carcinoma treated with carboplatin and paclitaxel as first-line treatment, four (36.3%) patients had a partial response, five (45.4%) stabilized the condition and two (18.1%) had disease progression with an overall response of 36%; the median disease-free survival was 7.9 months, and overall survival of 22.7 months (21, 22); Because there is no Peptide Receptor Radionuclide (PRRT)-based treatment in developing countries, it is convenient to use platinum-based chemotherapy in therapeutic regimens as a useful and accessible alternative with benefits established in this study and replicable in countries as Mexico.

## 5 | CONCLUSION

Mediastinal neuroendocrine tumor is an exceptionally rare occurrence that is difficult to diagnose due to its low incidence and the limited scientific evidence that exists on this disease, generally with a fatal outcome. Complete surgical resection has been the mainstay of therapy when a single-site malignant mass is found.

Its prognosis is usually poor despite surgical treatment; that's the reason; it requires complex management with systemic chemotherapy and radiotherapy to improve people's quality of life.

## CONFLICT OF INTEREST STATEMENT

The authors declare that they have no conflict of interest in this review.

## SOURCES OF FINANCING

The authors did not receive funding for this review.

## REFERENCES

1. Keita I, Nazario Dolz, A, Falcón G., Castillo L., Rodríguez Z, Romero L. Considerations

INTERMEDIATE-GRADE NEUROENDOCRINE MEDIASTINAL TUMOR A 38-YEARS- OLD MAN:  
CASE REPORT AND LITERATURE REVIEW

- regarding mediastinal tumors. *Rev Colomb Cir.* [Internet]. 2020;35(3),pp.472-482. Available in: <https://www.revistacirugia.org/index.php/cirugia/article/view/460>;
2. Quiroz Gutiérrez Fernando. *Human anatomy. Volume III. Respiratory, Digestive, and Genitourinary Apparatus. Glands of internal secretion and Organs of the senses.* Editorial Porrúa, S.A. Mexico. Forty-third edition, 2012.;
  3. Patnaik S, Malempati A, Uppin M, Susarla R. Rare mediastinal masses - Imaging review. *J Can Res Ther* [Internet]. 2021; 17: 13-21. Available in: <https://www.cancerjournal.net/text.asp?2021/17/1/13/297202>.;
  4. Oronsky B, Ma P, Morgensztern D, Carter C. Nothing But NET: A Review of Neuroendocrine Tumors and Carcinomas. *Neoplasia* [Internet]. 2017;19(12):991-1002. Available in: <https://www.sciencedirect.com/science/article/pii/S1476558617303470?via%3Dihub>;
  5. Kosmas K, Vamvakais I, Klapsinou E, Psychogiou E, Riga D. Primary Mediastinal Neuroendocrine Tumor: A Case of Atypical Carcinoid. *Cureus* [Internet] 2021; 22;13(1):e12853. Available in: <https://www.ncbi.nlm.nih.gov/pmc/articles/PMC7897398/> ;
  6. Melosky B. Advanced Typical and Atypical Carcinoid Tumours of the Lung: Management Recommendations. MDPI AG; 2018. Available from: <https://dx.doi.org/10.3747/co.25.3808>. doi:10.3747/co.25.3808.
  7. Fukushima T, Gomi D, Seno N, Gibo T, Kobayashi T, Sekiguchi N. Successful Salvage Chemotherapy with Streptozocin in a Patient with Mediastinal Atypical Carcinoid Tumor Who Had Relapsed after Various Prior Therapies. *Case Reports in Oncology* [Internet]. 2018;11(1):49-54. Available in: <https://www.karger.com/Article/FullText/477163>;
  8. Póvoa S, Azevedo D, Marques C, Barroca H, Costa A. Unknown primary large-cell neuroendocrine tumor. *Autopsy Case Rep* [Internet]. 2018;8(2):e2018025. Available in: <http://dx.doi.org/10.4322/acr.2018.025>;
  9. Adnan, Aadil; Kudachi, Shreyas; Ramesh, Sudha; Prabhash, Kumar; Basu, Sandip. Metastatic or locally advanced mediastinal neuroendocrine tumors: outcome with 177 Lu-DOTATATE-based peptide receptor radionuclide therapy and assessment of prognostic factors. [Internet]. 2019. Volumen 40 - Numero 9 - pp 947-957. Available in: [https://journals.lww.com/nuclearmedicinecomm/Abstract/2019/09000/Metastatic\\_or\\_locally\\_advanced\\_mediastinal.11.aspx](https://journals.lww.com/nuclearmedicinecomm/Abstract/2019/09000/Metastatic_or_locally_advanced_mediastinal.11.aspx);
  10. Schwartz LH, Litière S, De Vries E. RECIST 1.1. Update and classification: From the RECIST committee. *Eur J Cancer* [Internet]. 2016;62:132-137. Available in: <https://www.ncbi.nlm.nih.gov/pmc/articles/PMC5737828/pdf/nihms926904.pdf> ;
  11. Azam F, Latif MF, Farooq A, et al. Performance Status Assessment by Using ECOG (Eastern Cooperative Oncology Group) Score for Cancer Patients by Oncology Healthcare Professionals. *Case Rep Oncol.* [Internet] 2019;12(3):728-736. Available in: <https://www.ncbi.nlm.nih.gov/pmc/articles/PMC6792426/pdf/cro-0012-0728.pdf> ;
  12. Ventura L, Gnetti L, Silini E, Rindi G, Carbognani P, Rusc. Primary atypical carcinoid tumor of the mediastinum: a very rare finding. *Journal of Thoracic Disease.* [Internet]. 2017;9(4):E367-E372. Available in: <https://www.ncbi.nlm.nih.gov/pmc/articles/PMC5418266/> ;
  13. Costanzo L, Kewan, T, Kerwin K Daw H. Primary Mediastinal Small Cell Neuroendocrine Carcinoma Presenting with Superior Vena Cava Syndrome. *Cureus.* [Internet]. 2019. 11 (6), e4873. Available in: <http://dx.doi.org/10.7759/cureus.4873>;
  14. Bodei L, Sundin A, Kidd M, Prasad V, Modlin IM. The status of neuroendocrine tumor imaging: from darkness to light? *Neuroendocrinology.* [Internet]. 2015;101(1):1-17. Available in: <https://pubmed.ncbi.nlm.nih.gov/25228173/> ;

15. Rabiou S, Lakranbi M, Ghizlane T, Elfatemi H, Serraj M, Ouadnoui Y. Quelle chirurgie pour quelle tumeur du médiastin : expérience du service de chirurgie thoracique de CHU Hassan II de Fès. *Revue de Pneumologie Clinique* [Internet]. 2017;73(5):246-252. Available in: <https://www.sciencedirect.com/science/article/pii/S0761841716301626>;
16. Diaz-Perez J, Currás-Freixes M. Chromogranin A and neuroendocrine tumors. *Rev Endocrinología y Nutrición*. [Internet]. 2013; Vol(7):pp386-395. Available in: <https://www.elsevier.es/es-revista-endocrinologia-nutricion-12-articulo-cromogranina-a-tumores-neuroendocrinos-S1575092212003221> ;.
17. Kyriakopoulos G, Mavroeidi V, Chatzellis E, Kaltsas G y Alexandraki, K. Histopathological, immunohistochemical, genetic and molecular markers of neuroendocrine neoplasms. *Annals of Translational Medicine* [Internet], 2018; 6 (12), 252-252. Available in: <https://atm.amegroups.com/article/view/19995/html>;
18. Nardini M, Dunning J, Migliore M, Cerfolio R. Robotic resection of a middle mediastinal mass. *Journal of Visualized Surgery* [Internet]. 2018;2018(4):113-113. Available in: <http://jovs.amegroups.com/article/view/19627/19607>;
19. Hidaka T, Okuzumi S, Matsuhashi A, Takahashi H, Hata K, Shimizu S and Iwasaki Y. Large Cell Neuroendocrine Carcinoma of the Mediastinum Successfully Treated with Systemic chemotherapy after Palliative Radiotherapy. *Inter Med* (Tokio, Japon). [Internet]. 2019. 58 (4), 563–568. Available in: <http://dx.doi.org/10.2169/internalmedicine.0437-17>;
20. Basu S, Thapa P, Parghane R. 177Lu-DOTATATE peptide receptor radionuclide therapy in metastatic or advanced and inoperable primary neuroendocrine tumors of rare sites. *World Journal of Nuclear Medicine* [Internet]. 2017;16(3):223. Available in: <http://www.wjnm.org/article.asp?issn=1450-1147;year=2017;volume=16;issue=3;spage=223;epage=228;aulast=Thapa>;
21. Maurizi G, D'Andrilli A, Vanni C. Salvage resection of advanced mediastinal tumors. *J Thorac Dis* [Internet]. 2019;9;11(Suppl 13):S1653-S1661. Available in: <https://www.ncbi.nlm.nih.gov/pmc/articles/PMC6706622/> ;.
22. Hamaji M, Allen M, Cassivi S. The role of surgical management in recurrent thymic tumors. *Ann Thorac Surg* [Internet]. 2012; 94(1):247-254. Available in: <https://www.annalsthoracicsurgery.org/action/showPdf?pii=S0003-4975%2812%2900454-7>;

**How to cite this article:** Vanessa M.S.L., Roberto M.C.L., Agustín S.T.J., Yereldi N.C.A., Valeria J.B.M. **Intermediate-Grade Neuroendocrine Mediastinal Tumor a 38-Years- Old Man: Case Report and Literature Review.** *Journal of Current Medical Research and Opinion.* 2021;967–974. <https://doi.org/10.15520/jcmro.v4i06.428>

INTERMEDIATE-GRADE NEUROENDOCRINE MEDIASTINAL TUMOR A 38-YEARS- OLD MAN:  
CASE REPORT AND LITERATURE REVIEW

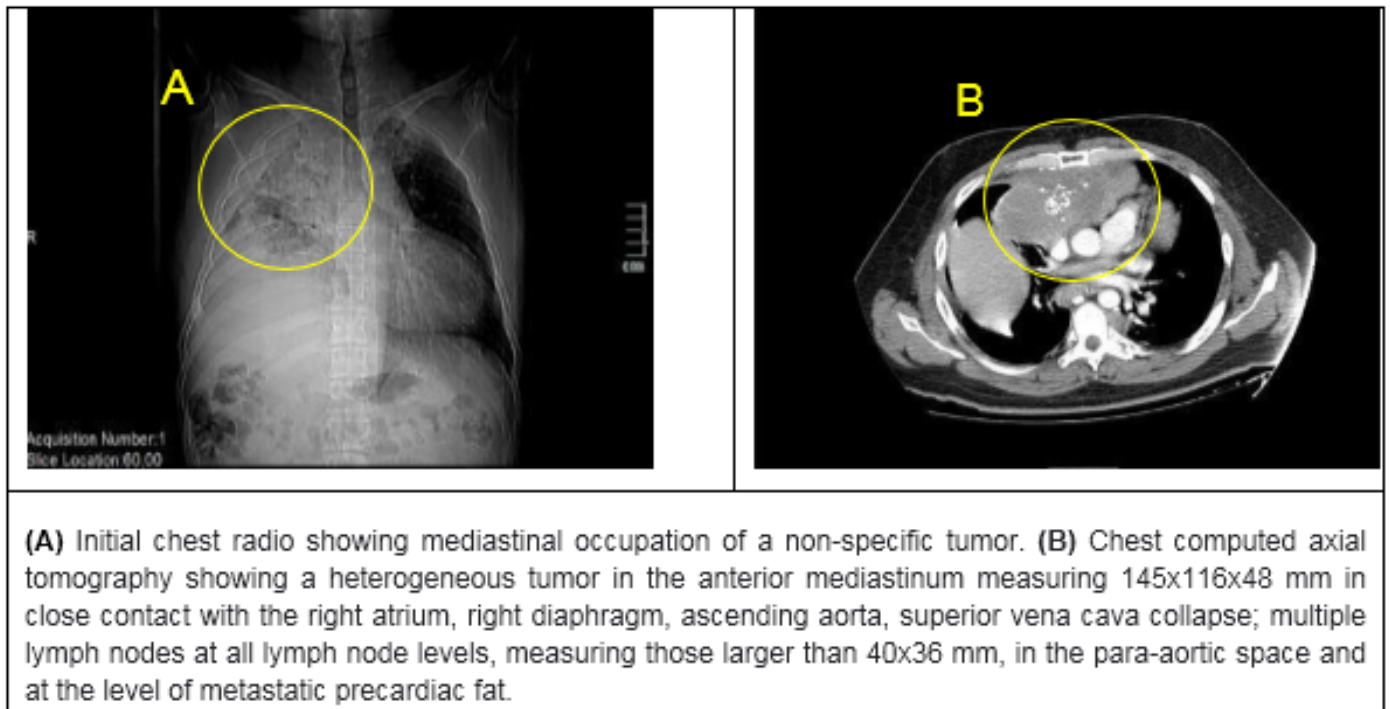


FIGURE 1: Diagnostic studies

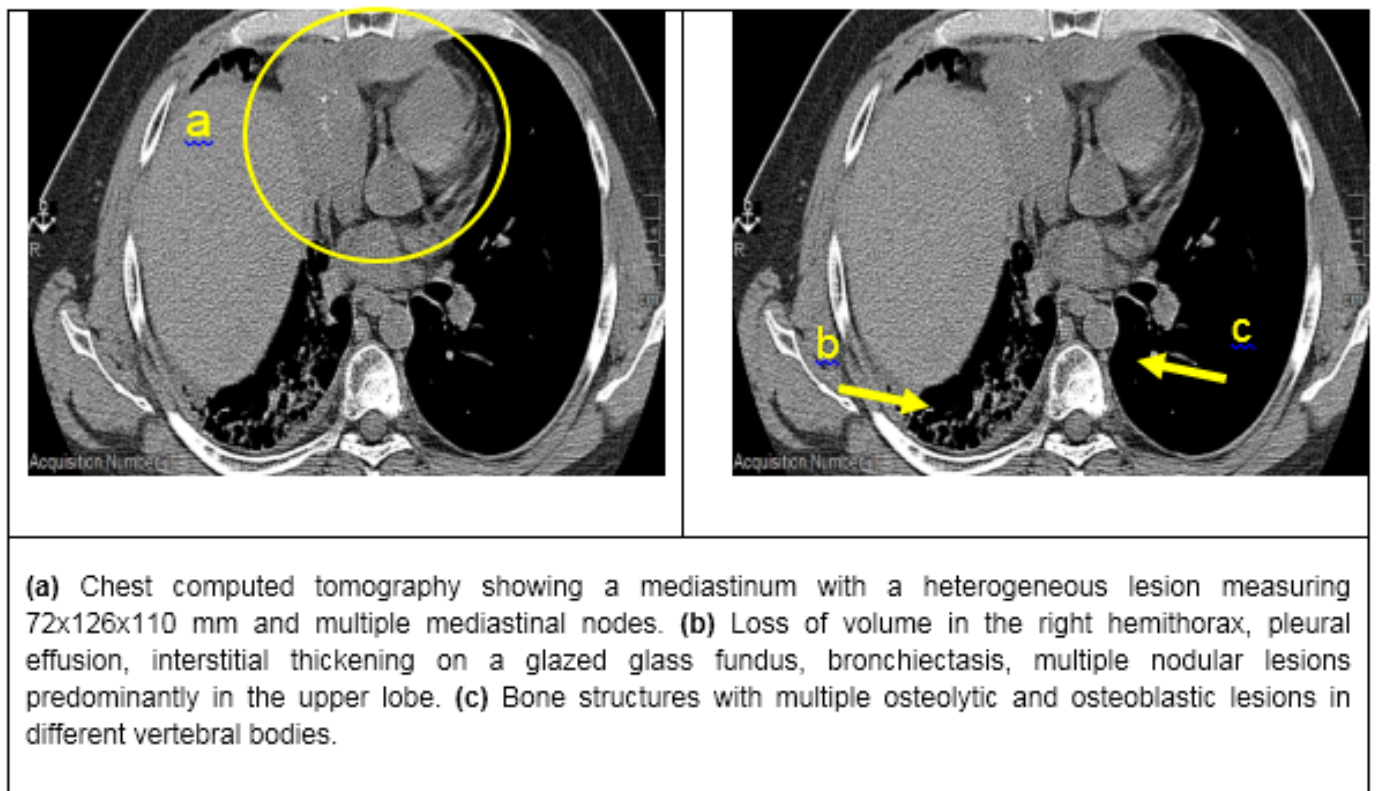
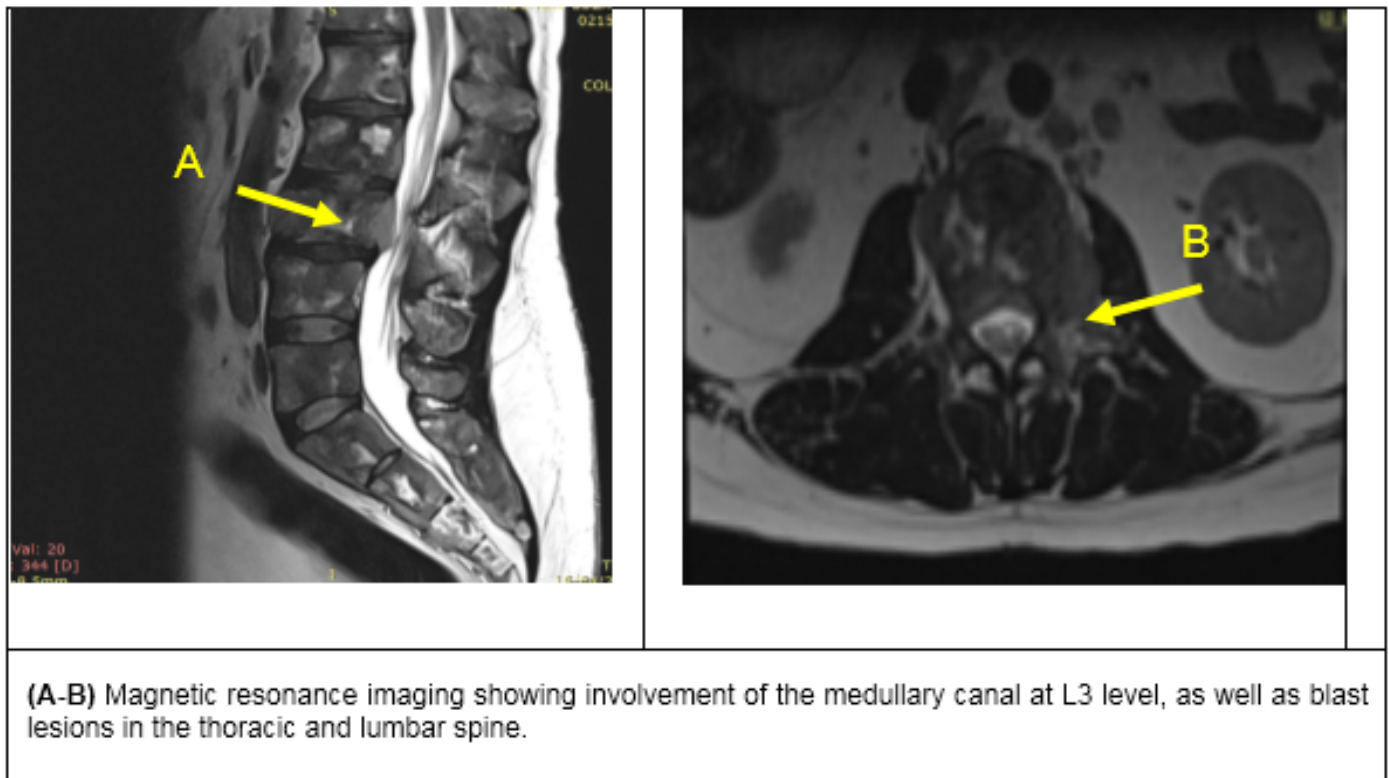
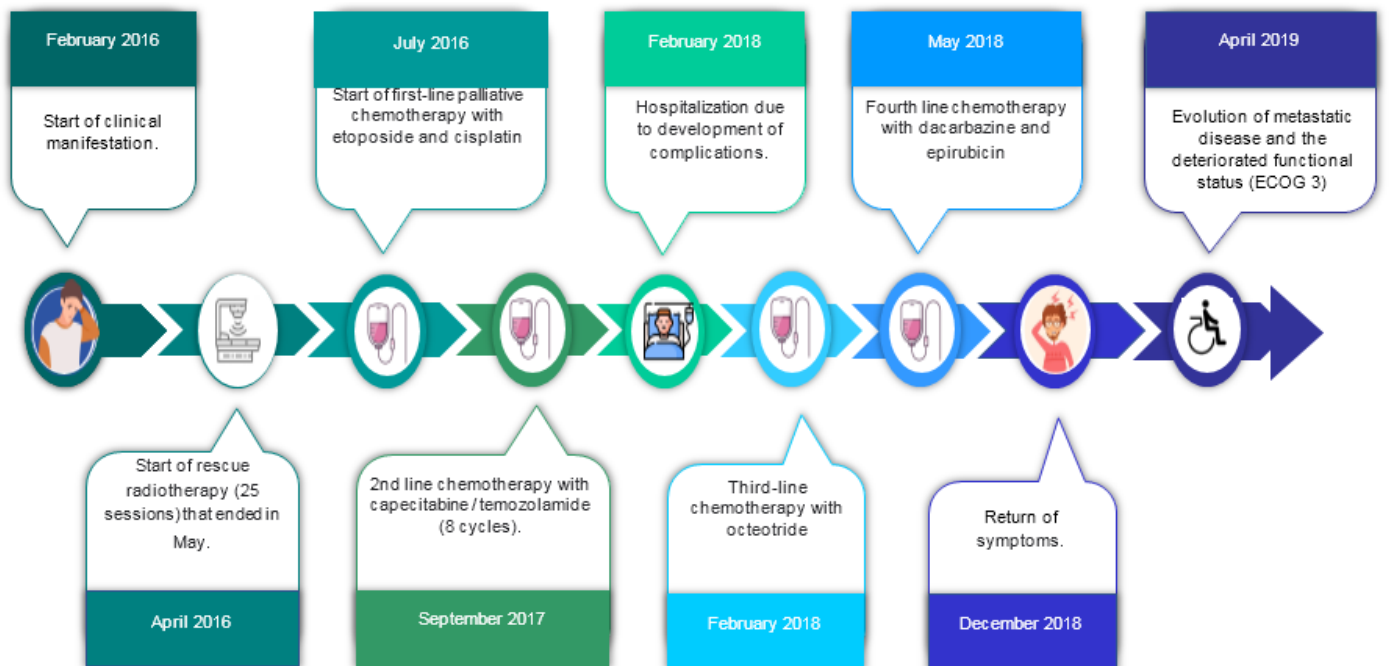


FIGURE 2: Control chest computed tomography.



**FIGURE 3:** Magnetic Resonance



**FIGURE 4:** Timeline



INTERMEDIATE-GRADE NEUROENDOCRINE MEDIASTINAL TUMOR A 38-YEARS- OLD MAN: CASE REPORT AND LITERATURE REVIEW

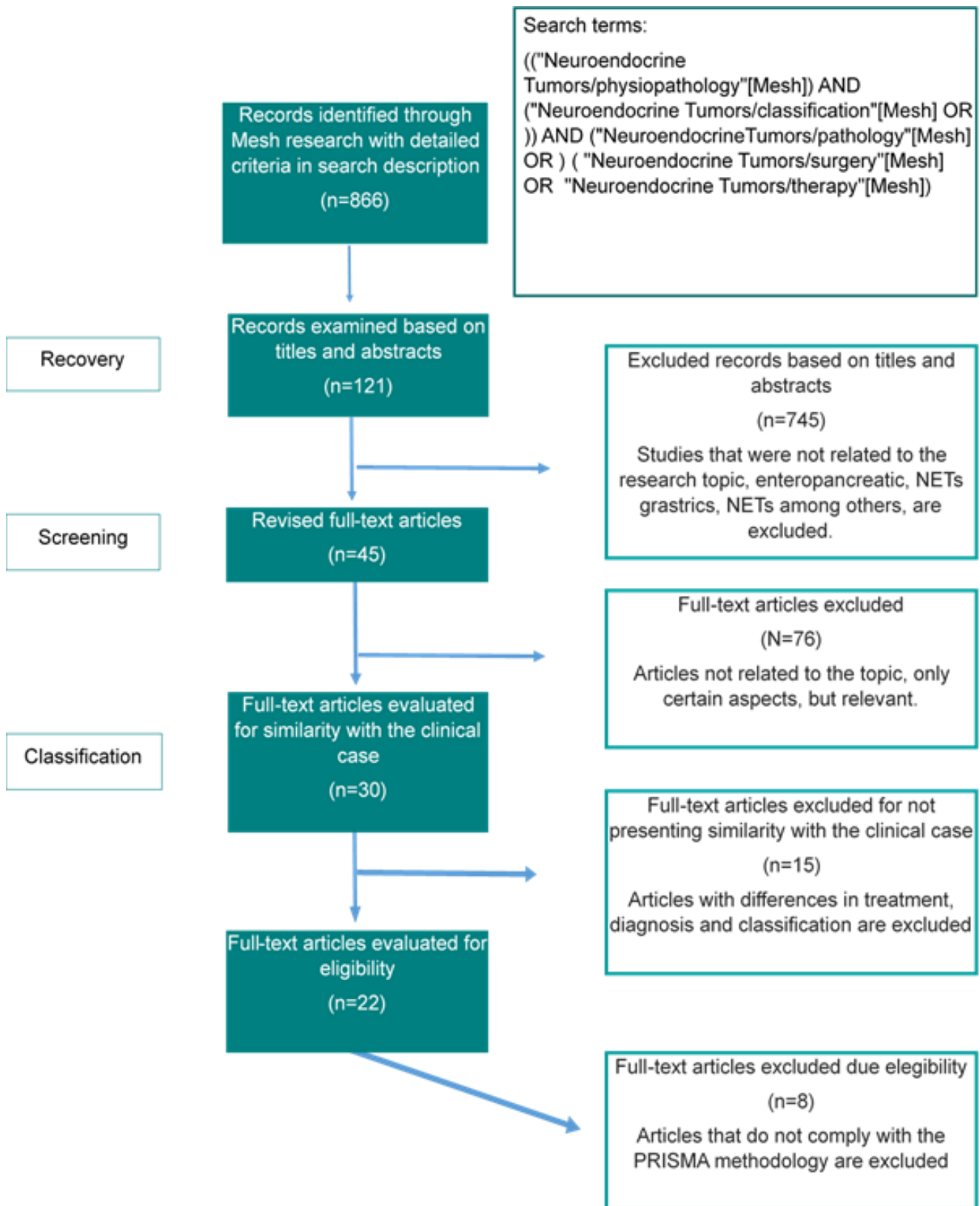


FIGURE 5: Diagram 1